

The role of femtolaser in cataract surgery

Laser femtosekundowy w chirurgii zaćmy

Nagy Zoltán Z.¹, Szaflik Jacek P.²

¹ Department of Ophthalmology, Semmelweis University, Budapest, Hungary

Head: Professor Nagy Zoltán Z., MD, PhD

² Department of Ophthalmology, Medical University of Warsaw

Head: Professor Szaflik Jerzy, MD, PhD

Streszczenie:	Lasery femtosekundowe, które z powodzeniem stosowane są już w chirurgii rogówki, od niedawna znalazły zastosowanie także w operacjach na soczewce. Zastosowanie ich umożliwia wykonanie kapsuloreksji o idealnych centracji i średnicy, upłynnienie bardziej miękkich soczewek oraz fragmentację twardszych soczewek, która ułatwia podzielenie jądra bez konieczności wykorzystania energii fakoemulsyfikatora. Mogą być także użyte do wytworzenia ran rogówkowych (tuneli) o dowolnych lokalizacji i kształcie oraz do redukcji astygmatyzmu za pomocą nacięć łukowatych na odpowiedniej głębokości rogówki. Należy się spodziewać, że w najbliższej przyszłości ta technika operacji będzie coraz bardziej akceptowana i rozpowszechniana, ponieważ pozwala na zachowanie bardzo dobrej kontroli nad poszczególnymi elementami zabiegu.
Słowa kluczowe:	femtolaser, laser femtosekundowy, chirurgia refrakcyjna soczewki, kapsuloreksja, kapsulotomia, upłynnienie, fragmentacja, tunel rogówkowy.
Summary:	Having been very successful in corneal surgery, femtolasers were recently introduced into the surgery of crystalline lens. The most important indications and advantages include: perfectly centered and sized capsulotomy, liquefaction of softer lenses and fragmentation of harder lenses which allows for chopping the nucleus without the use of phaco energy. Femtolaser can also be used for creating corneal wounds (tunnels) of any size at any location, and in order to manage the preoperative astigmatism using arcuate incisions at the desired depth within the cornea. Because of controlled steps in cataract surgery, wide acceptance and spread is to be expected.
Key words:	femtolaser, femtosecond laser, refractive cataract surgery, capsulorhexis, capsulotomy, liquefaction, fragmentation, corneal wound.

Femtolasers operate at high energy levels and very short pulses (in the femtosecond range). The usual wavelength is 1053 nm, and Nd-glass is the active laser medium. This wavelength operates at the near infrared range of electromagnetic spectrum. The depth of the femtolaser effect can be precisely controlled and focused within the eye allowing to achieve a very precise cut. When the laser beam is applied onto the incision site, microplasm is created within the tissue at the depth of 1 μm . In the operating microscope, the surgeon may observe a fine line, consisting of whitish gas bubbles within the cut plane. The laser impulses can be applied onto any plane, therefore horizontal, vertical and any other type and size of incisions can be made. This features can be very well used in corneal surgery and during the surgery of the crystalline lens. Until recently, femtolasers were used only for corneal surgery. However, based on the technical development achieved by the researchers with LenSx-Alcon, FDA approved the femtolaser surgery of the crystalline lens in 2010 for capsulorhexis, lens fragmentation and liquefaction as well as for creating corneal wounds and lastly also for creating arcuate incisions to control preoperative astigmatism. The first human treatment ever was performed in August 2008 in Budapest, Semmelweis University by Dr Zoltan Z. Nagy (1).

It is still debated what the most important advantages of femtolaser-assisted refractive cataract surgery over manual

phacoemulsification are. The most important features can be seen below, but in summary based on the experience of previous years one can conclude: exact diameter and central position of capsulorhexis, sparing of phacoemulsification energy, compact corneal wounds in the desired position and size, much higher predictability compared to traditional phacoemulsification and enabling the surgeon to control all critical steps of cataract surgery with micrometer accuracy (2,3). These issues came into focus with the invention of premium lenses, which imposed more precise steps in surgical cascade. For example, if a capsulorhexis is decentered or larger than the desired 5.00 mm, it may result in a shift of the implanted posterior chamber lens, causing myopic/hyperopic refractive change, increase in higher order aberrations, glare and halo effects (2-5). Because ophthalmologists operate on younger and younger patients, the quality of vision and the ability to see clearly at all distances are required, exerting tremendous pressure on the surgeon. These surgical requirements can be met only with perfect technology.

The crystalline lens fragmentation may follow a cylindrical or a cross pattern, upon the choice of the surgeon. Cylindrical pattern includes concentric rings starting from the back of the crystalline lens (about 400 μm away from the posterior capsule towards the anterior capsule). The surgeon controls the position of the laser beam in the crystalline lens at every second. The cylindrical pattern is recommended for cataracts up to

grade 2.0 according to the LOCS system. The aim is to liquefy the central lens material and to enable the surgeon to aspirate the lens material using only the I/A (irrigation, aspiration) programme of the phaco machine. This is intended for refractive lens exchange, especially in younger patients with high myopia and hyperopia, or in patients in whom the accommodation needs to be restored.

The cross (radial) pattern is recommended for harder nuclei up to +4.0 grade according to the LOCS system. The four cuts (demarking the four quadrants of the lens) are obligatory, but the surgeon may choose a 6- or an 8-cut patterns (cake pattern). The 4 cuts are very useful to „crack” the nucleus without using any phaco energy (no need to make a groove with the phaco head using ultrasound energy) at the beginning of the surgery. The consecutive phacoemulsification is then similar to the traditional procedure. Recently, the hybrid pattern was developed, which is also used for harder nuclei, i.e.: in the central .35 mm zone a liquefaction is used simultaneously with the fragmentation. During the first step, the surgeon removes the central portion, and then chops the lens more easily. The last pattern became popular very quickly.

In order to create a corneal wound one can predefine any parameter: wound geometry (uniplanar, biplanar, multiplanar), wound length and width. The location of the wound can be customized (upper or temporal incisions, etc.) for the convenience of the surgeon.

It is very important to note that the corneal wound is a self-sealing type, so it does not open upon creation. The surgeon may make an incision at the O.R. or outside it, and it may be created hours before. It is an important factor, because if the femtolaser will be used by many surgeons in different O.R.-s, it is recommended to arrange a separate laser room for better efficiency.

Indications, Inclusion and Exclusion criteria

Indications for lens liquefaction

- Refractive lens exchange, mainly for high myopia and high hyperopia
- Cataract grading max. 2.0 according to the LOCS system, or age up to 50 yr
- Traumatic cataract (lens just started to get opaque), age below 50 yr

Indications for lens fragmentation

- Cataract grading between 1.5 and 4.5 (LOCS)
- No age limit, but liquefaction is usually better in younger patients
- Traumatic cataract, when the nucleus appears to be harder

Contraindications

- Non-dilating pupil

Relative contraindications

- Brown or black cataract
- White cataract (This only constitutes a relative contraindication because the method is perfect for capsulorhexis. However, cuts cannot be made within the white lens material.)

Sequence of the femtolaser procedure

- Patient selection
- Consenting
- Patient head positioning
- Topical anesthesia
- Capsulorhexis
- Lens liquefaction or fragmentation
- Astigmatism correction (arcuate incisions at 80% depth)
- Corneal wound

1. Patient Selection and Preparation

It is very important that the patients be cooperative and have a positive attitude. They should understand the importance of laser treatment and accept possible problems associated with this technology. The ideal patient can tolerate some pressure feeling during treatment, is not too anxious and able to look into the fixating light of the operating microscope or in the patient interface; they should also be able to rest for a couple of minutes. Ideally, the right candidate has no cataract (refractive lens exchange) or has a nuclear cataract grade less than 4.0 according to the LOCS system. Apart from a slit lamp examination, the use of Pentacam is recommended, because the density of the crystalline lens can be easily assessed preoperatively. Moreover the surgeon gains important information about the patient's ocular anatomy. The lens density can also be measured using the in-built OCT. However, this is recommended only when there is no Pentacam available.

2. Laser Docking and Coupling

The femtolaser treatment is performed in a supine position. The most important aspect is to ensure a resting position with the eye kept absolutely horizontally. If it is not achieved, the eye will be tilted and so will the crystalline lens. As a result the surgeon will not be able to fix the PI properly (Fig. 1.).



Fig. 1. The Alcon-LenSx femtolaser for cataract surgery.
Ryc. 1. Femtolaser do chirurgii zaćmy LenSx firmy Alcon.

3. Image-guided Alignment of Laser Treatment

One of the most important features of the commercially available femtolasers is the in-built OCT imaging system (Fig. 2., 3.).

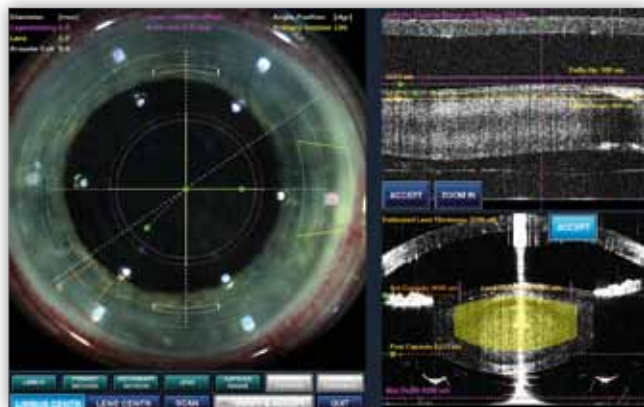


Fig. 2. The OCT image of the anterior segment. The OCT identifies the anterior and posterior capsules and measures the density of the crystalline lens. The surgeon plans the corneal cuts on the screen.

Ryc. 2. Obraz OCT przedniego odcinka. Za pomocą OCT rozpoznawane są przednia i tylna torebka soczewki oraz określana jest gęstość soczewki. Na ekranie chirurg planuje nacięcia wykonywane laserem.

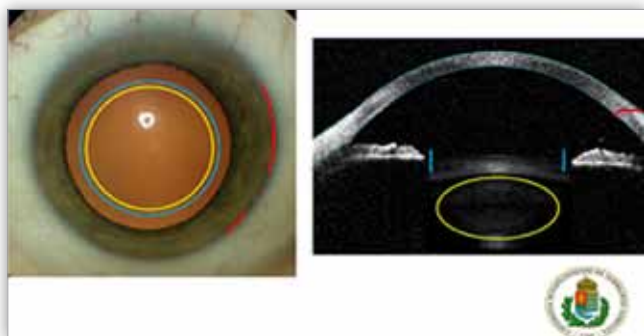


Fig. 3. The proprietary image-guided system allows the surgeon to take a pre-operative OCT image and position the planned incisions as well as photolysis patterns on the patient's eye. The blue and yellow overlays represent the lens photolysis and capsulotomy patterns. The red one represents the corneal incisions. Size and position of all patterns can be pre-programmed and adjusted for the ultimate surgeon control.

Ryc. 3. Wbudowany system oparty na obrazowaniu pozwala chirurgowi wykonać przedoperacyjne badanie OCT i określić, jakie będą: umiejscowienie nacięć i ich kształt oraz typ i zakres fragmentacji jądra soczewki. Kolorami niebieskim i żółtym oznaczono wielkość kapsuloreksji i zakres fotolizy soczewki. Koloriem czerwonym zaznaczono nacięcia w rogówce. Wielkość wszystkich nacięć i ich umiejscowienie mogą być zaprogramowane wcześniej, a następnie dowolnie regulowane przez chirurga.

It is very useful to plan all treatment details and to have a safe distance from the posterior and anterior capsule, as well as to create a perfect corneal wound. Has the eye been centered, the OCT examination is performed. After inserting the PI, the computer projects circles and lines (limbal area, capsulotomy, corneal wounds) on the surface of the eye. The surgeon controls the central position of the projected circles and lines, and performs the first OCT measurement. In the first step, the surgeon identifies the anterior and posterior capsule and plans the capsular treatment. During the second step, the surgeon identifies the anterior and posterior capsule and sets the machine manually, indicating where the cuts within the lens should be. During the third OCT measurement, the corneal incisions are planned and can be modified. As soon as the treatment param-

eters are accepted, all data is transferred to the computer of the femtolaser, and the treatment can start in a few seconds, just by pressing down the treatment pedal. The entire femtolaser treatment does not usually exceed 90 seconds.

4. Laser-assisted steps

The laser-assisted steps include the following:

- cut in the anterior capsule (capsulorhexis),
- cut in the lens (cylindrical or cross pattern),
- cut in the cornea (uni-, biplanar, multiplanar or arcuate).

Cataract surgery

In the first step the surgeon identifies the corneal wound and opens it with a blunt spatula. Afterwards the anterior chamber should be filled with viscoelastic material. Then, the surgeon finds the deepest cut within the lens and lifts the cut portion of the anterior capsule with a rhexis needle (cystotome) or rhexis forceps. The contour of the femtolaser cut should be meticulously followed and the round shape anterior capsule can be removed this way (Fig. 4.).

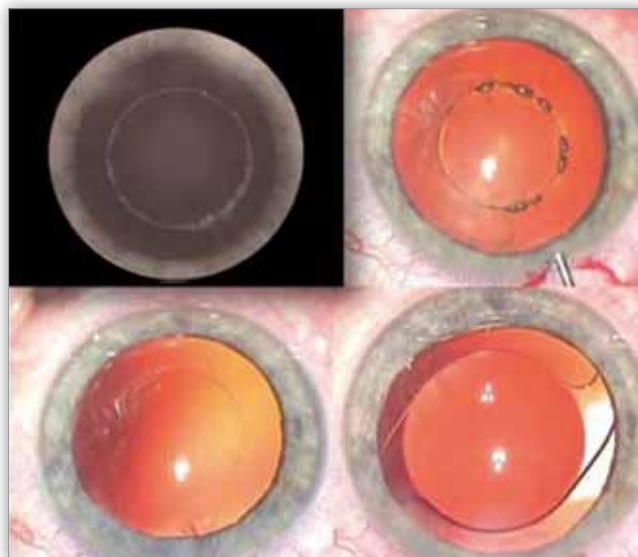


Fig. 4. Capsulotomy incision on the screen of the femtolaser – a., under the operating microscope – b., round and perfect capsulotomy just after removing the crystalline lens – c. At the end of the surgery, a well centered PCL within the capsular bag – d.

Ryc. 4. Kapsulotomia widoczna na ekranie femtolasera – a., w mikroskopie operacyjnym – b., okrągła, idealna kapsulotomia po usunięciu soczewki – c. Po zakończeniu zabiegu prawidłowa centracja implantu w torebce soczewki – d.

Pulling out with an abrupt hand movement can cause anterior tear which might lead to anterior and posterior capsular damage. Small tags can occur especially during the learning curve. After removing the capsule a slow hydrodissection should be performed. It should be carried out slowly and softly, because gas bubble may appear within the crystalline lens after fragmentation and with slow hydrodissection the gas exits through the anterior capsule without a problem. An abrupt hydrodissection may result in a blockage syndrome, causing rupture of the posterior capsule. We have never had such a problem; with cautious technique it can be avoided in 100%. After a successful hydrodissection,

the surgeon enters the eye with the phaco head and the chopper. It is advised to grab the lens near the vertical fragmentation line with 300 mmHg and to chop it into 2 pieces using the chopper. Later turn the lens and repeat the movement with the other fragmentation line. Having 4 quadrants of the nucleus, it is easy to remove them using minimum phaco energy and time, so the CDE (cumulative dissipation energy) can be minimised. After nucleus removal, the cortex should be removed with the I & A similarly to manual phacoemulsification. Sometimes larger epinucleus remains like a „bowl”. It can be removed with the epinucleus programme of the phaco machine or simply with the I & A. The posterior chamber lens implantation is similar to the previously described surgical technique. At the end of surgery, the wound should be checked, most of the cases do not require hydration, because the wound is self-sealing. The cases of rupture or other surgical trauma might require hydration. According to the European Endophthalmitis Study, intracameral antibiotic might be used in order to avoid postoperative intraocular complications.

In case of softer lenses, after removing the anterior capsule, hydrodissection is usually not required and the central nucleus can be easily aspirated using the I & A tip only. The depth of the anterior chamber should be closely monitored and maintained during the surgery, especially in high myopes and sometimes also hyperopes, to ensure safety. It is particularly important in younger patients operated under topical (drop) anesthesia. They can be anxious and exerting pressure with the speculum may consequently cause the IOP elevation.

Conclusions

Femtolasar treatment of the crystalline lens increases safety, efficacy and predictability of the surgery. Surgical skill and wisdom are still needed to avoid possible complications, which might occur during lens surgery. During the well prepared pro-

cedures (careful patient information and selection, proper PI insertion, well designed and performed capsulotomy, lens fragmentation/liquefaction, corneal wound and astigmatism correction) the safety of refractive cataract surgery increases and the patients can benefit from all advantages of the premium lenses. Pricing is an important factor, affecting how fast the procedure will spread, but with the aging population and the increasing number of cataract extraction procedures, wide acceptance and use is expected in the near future.

References:

1. Nagy ZZ, Takacs A, Filkorn T, Sarayba M: *Initial clinical evaluation of an intraocular femtosecond laser in cataract surgery*. J Refract Surg 2009, 25, 1053-1060.
2. Nagy ZZ, Kranitz K, Takacs AI, Mihaltz K, Kovács I, Knorz MC: *Comparison of intraocular lens decentration parameters after femtosecond and manual capsulotomies*. J Refract Surg 2011, 27, 564-569.
3. Kranitz K, Takacs A, Mihaltz K, Kovács I, Knorz MC, Nagy ZZ: *Femtosecond laser capsulotomy and manual continuous curvilinear capsulorrhexis parameters and their effects on intraocular lens centration*. J Refract Surg 2011, 27, 558-563.
4. Ecsedy M, Mihaltz K, Kovács I, Takács A, Filkorn T, Nagy ZZ: *Effect of Femtosecond Laser Cataract Surgery on the Macula*. J Refract Surg 2011, 31, 717-722.
5. Mihaltz K, Knorz MC, Alio JL, Takacs AI, Kranitz K, Kovács I, Nagy ZZ: *Internal aberrations and optical quality after femtosecond laser anterior capsulotomy in cataract surgery*. J Refract Surg 2011, 27, 711-716.

The study was originally received 25.09.2012 (1405)/
Praca wpłynęła do Redakcji 25.09.2012 r. (1405)
Accepted for publication 30.09.2012/
Zakwalifikowano do druku 30.09.2012 r.

Reprint requests to (Adres do korespondencji):
Zoltan Z. Nagy, Professor of Ophthalmology
Department of Ophthalmology, Semmelweis University
Maria u. 39.
H-1085 Budapest, Hungary
e-mail: nz@szem1.sote.hu and zoltan.nagy100@gmail.com